Section Editor: Steven F. Harwin, MD

SPOTLIGHT ON spine

A Method for Intraoperative Repositioning of the Cervical Spine During Posterior Cervical Surgery

Addisu Mesfin, MD; Joseph P. Gjolaj, MD; Mesfin A. Lemma, MD

Abstract: Positioning of the head during posterior cervical decompression and fusion requires invasive techniques (eg, pins placed through the skull) and manual repositioning intraoperatively. This article describes a new technique with a noninvasive device for such positioning. From February 2005 until June 2010 at our institution, 94 patients underwent posterior cervical decompression and fusion with instrumentation. All were positioned prone, and their heads were positioned via our technique and customized device. There were no intraoperative complications secondary to this positioning. The device is easy to use, avoids complications associated with invasive devices, and obviates intraoperative repositioning during posterior approaches.

The development of cervical spondylotic myelopathy involves static factors, such as a developmentally narrowed spinal canal, and dynamic factors, both of which result in repetitive injury to the spinal cord depending on the position of the cervical spine.[1] In the presence of posterior abnormality, hyperextension of the cervical spine can cause narrowing of the spinal canal because of buckling, invagination of the ligamentum flavum, and shingling of the laminae.[1-3] Therefore, during posterior cervical decompression and fusion, the patient is typically positioned in a neutral or slightly flexed position until spinal cord decompression is achieved. Cervical spine position is then adjusted by increasing extension to achieve a more anatomic position for final fixation and arthrodesis.

Various methods exist for positioning the cervical spine during posterior cervical decompression and fusion, including Mayfield head holders or tongs (Ohio Medical Instrument Co, Cincinnati, Ohio) with traction,[4] various attachments to the OSI Jackson table (Mizuho OSI, Union City, California),[4,5] and positioning cushions. We present a novel method of intraoperative repositioning of the cervical spine for improved lordosis during posterior cervical decompression and fusion that is noninvasive and easy to use, allows for microchanges in alignment, and does not require intraoperative adjustment.

Materials and Methods

This study was approved by our institutional review board.

From February 2005 until June 2010, ninety-four patients underwent posterior cervical spine fusion and decompression by 1 surgeon at our institution (M.A.L.). Forty-one women and 53 men had an average age at the time of surgery of 67.1 years (range, 45.7-88.7 years). The diagnoses were cervical myelopathy and stenosis (n=93) and ossification of the posterior longitudinal ligament (n=1). All patients were positioned via the technique described below. All patients underwent instrumented fusion and laminectomy at the following levels: C3-C6 (n=64), C3-C5 (n=11), C4-C6 (n=5), C3-T2 (n=9), C3-C7 (n=2), C5-T2 (n=1), C6-T2 (n=1), and C5-T1 (n=1). We evaluated for intraoperative complications (defined as shifting of the head once the device was inflated, the surgeon having to scrub out and manually reposition the head, and the device being removed and replaced with an alternative head-positioning device) associated with the use of the technique and device.

Drs Mesfin, Gjolaj, and Lemma are from the Department of Orthopedic Surgery, The Johns Hopkins University, Baltimore, Maryland.

Drs Mesfin, Gjolaj, and Lemma have no relevant financial relationships to disclose.

Correspondence should be addressed to: Mesfin A. Lemma, MD, c/o Elaine P. Henze, BJ, ELS, Editorial Services, Department of Orthopedic Surgery, Johns Hopkins Bayview Medical Center, 4940 Eastern Ave, #A665, Baltimore, MD 21224-2780 (ehenze1@jhmi.edu).

doi: 10.3928/01477447-20110627-19

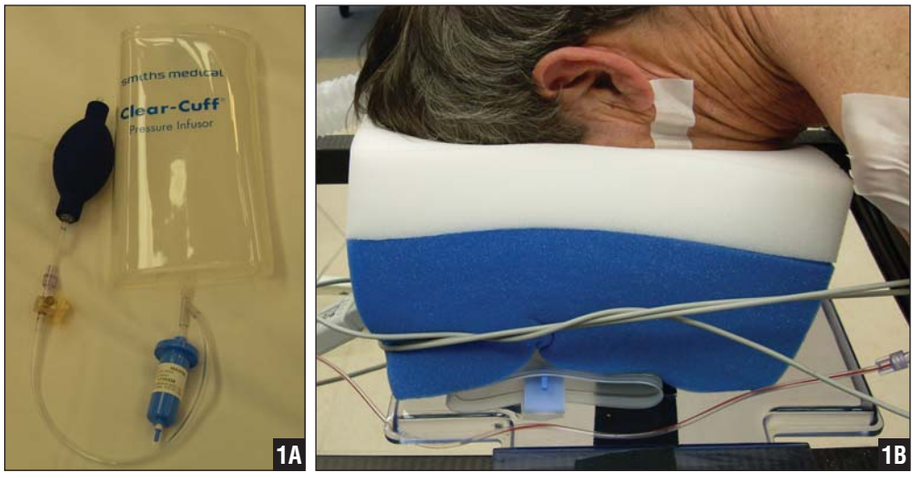

Figure 1: Once the patient has been positioned prone on the OSI Jackson table, the pressure bag (A) is carefully placed underneath the face support cushion (B) in the midline of the face and at the level of the forehead.

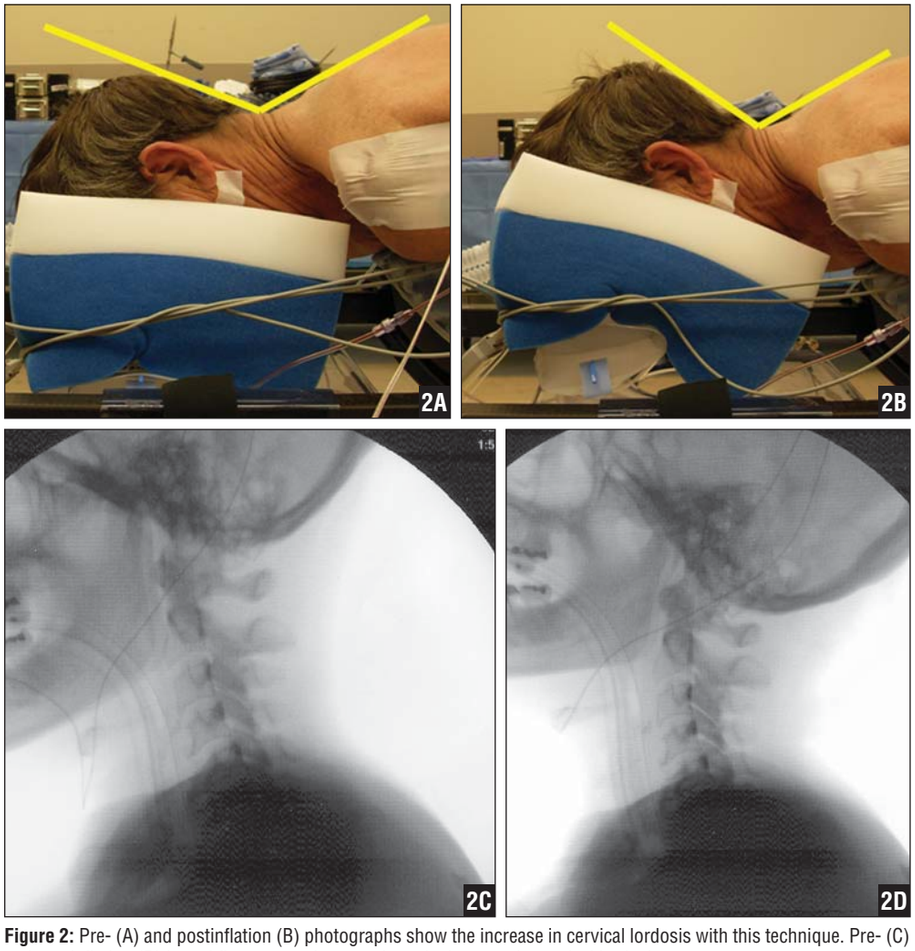

Figure 2: Pre- (A) and postinflation (B) photographs show the increase in cervical lordosis with this technique. Pre- (C) and postinflation (D) lateral fluoroscopy images show the increase in cervical lordosis.

Surgical Technique

With the patient under general anesthesia, endotracheal intubation is performed. Baseline somatosensory-evoked potentials and motor-evoked potentials are obtained. The patient is transferred to the OSI Jackson table and positioned prone with the arms tucked at the side and the bony prominences (thorax, sternum, elbows, iliac crests, knees) well padded.

In the prone position, the patient's face is supported by a foam cushion (Gentle Touch Headrest Pillow with Intubation Slot, Mizuho OSI, Tokyo, Japan). A deflated intravenous (IV) pressure infusor (Clear-Cuff Pressure Infusor, Smiths Medical, Dublin, Ohio) is placed underneath the foam support. This pressure bag should be carefully positioned in the midline of the face and at the level of the forehead (Figure 1). The patient's eyes are checked again to verify that there is no extrinsic compression. The neck is maintained in a neutral or slightly flexed position.

After sterile prepping and draping, a standard midline approach to the posterior cervical spine is performed. After appropriate levels are exposed and confirmed via fluoroscopy, spinal fixation is placed, and then laminectomy, ligamentum flavum excision, and spinal cord decompression of the appropriate levels are performed.

At this point, the anesthesiologist is asked to inflate the IV pressure infusor until the desired amount of cervical extension has been achieved (Figure 2). The rod is then contoured appropriately, placed in

the screw heads, and locked in place. Bone graft is placed, followed by drain placement and layered wound closure. The patient is transferred supine onto a hospital bed and a cervical collar is applied.

Results

None of the 94 patients experienced intraoperative complications associated with our cervical spine positioning technique and device.

Discussion

Deciding on the most appropriate surgical approach to treating cervical spondylotic myelopathy depends on numerous patient and anatomic considerations. For patients in whom posterior cervical decompression and fusion is deemed the most effective strategy, preoperative patient positioning and intraoperative repositioning are important considerations to minimize the risk of cord injury while maximizing restoration of cervical alignment.

One common technique is the use of Mayfield head holders or tongs. Tongs are typically used with 3 traction lines: 2 in neutral and 1 aimed upward to increase cervical extension. The Mayfield head holder involves the placement of cranial pins that have been associated with pin-site pain, risk of intracranial epidural hematoma, cerebrospinal fluid rhinorrhea, and breakage of the head holder.[6-11] In 3 reports, epidural hematoma after application of Mayfield head holder developed secondary to fractures of the cranium caused during pin insertion, 2 in children and 1 in an adult.[6,7,11] Pediatric patients may be at higher risk because of their thinner cranial bones, even with less force (40-60 lbs) than the standard 60 to 80 lbs used for adults. Clinically, when an epidural hematoma develops from pin penetration of the cranium, the patients presents with Glasgow Coma Scale changes, nausea, and vomiting within 6 hours to 10 days postoperatively. Computed tomography scan of the head is warranted for diagnosis and prompt evacuation of the hematoma via craniotomy.[6,7,11]

Breakage and cracks of the Mayfield head holder have also been reported.[8,10,12] In those 3 cases, the head holders had been used for 8 to 14 years. One of the breaks occurred intraoperatively, and spinal cord injury was avoided by the patient's head falling onto the surgeon's lap.[10] The other 2 cases occurred during preoperative checks and pin insertion. If the head holder is to be used, then routine preoperative checks for damage, radiographs to detect fatigue fractures in the head holder, and scheduled equipment maintenance with the manufacturer are recommended.[8]

Another disadvantage of the Mayfield head holder is that it requires a member of the surgical team to readjust its position at the appropriate point during the procedure. Other head-positioning techniques include a 2-person approach in which 1 person lifts the patient's head and the other builds up the face support with, for example, folded towels. This approach can be cumbersome and does not allow for fine adjustments.

In our series of 94 patients who were positioned for posterior cervical decompression and fusion with our technique and device, none experienced a positioning-related intraoperative complication.

The use of this readily available device allows for a noninvasive, low-cost, safe, and controlled cervical extension without the risk of complications associated with Mayfield tongs and other similar devices. Our device/technique avoids the costs of maintenance of the Mayfield head holder and of obtaining radiographs of the head holder to ensure the absence of fatigue fractures; it also avoids the devastating consequences of an epidural hematoma caused by pin penetration and the health care costs associated with its diagnosis and management. With our technique, comparison of pre- and postinflation images show the substantial increase in cervical extension that can be obtained (Figure 2). This technique also eliminates the need for a member of the surgical team to break scrub to adjust the neck position, as is required with the Mayfield head holder, or to build up face support, as is needed with other techniques. The senior author (M.A.L.) has been using this technique for the past 5 years with no complications. Future studies may focus on evaluation of the device/technique in multicenter trials.

References

1. Rao R. Neck pain, cervical radiculopathy, and cervical myelopathy: pathophysiology, natural history, and clinical evaluation. *J Bone Joint Surg Am*. 2002; 84(10):1872-1881.
2. Chen IH, Vasavada A, Panjabi MM. Kinematics of the cervical spine canal: changes with sagittal plane loads. *J Spinal Disord*. 1994; 7(2):93-101.
3. Chen CJ, Hsu HL, Niu CC, et al. Cervical degenerative disease at flexion-extension MR imaging: prediction criteria [published online ahead of print February 11, 2003]. *Radiology*. 2003; 227(1):136-142.
4. Callahan RA, Brown MD. Positioning techniques in spinal surgery. *Clin Orthop Relat Res*. 1981; (154):22-26.
5. Kyoshima K, Kobayashi S, Sugita K. Fixation system for cervical spinal operation: application of the head fixation system and multipurpose cervical frame. *Neurosurgery*. 1987; 21(4):591-594.
6. Baerts WD, de Lange JJ, Booij LH, Broere G. Complications of the Mayfield skull clamp. *Anesthesiology*. 1984; 61(4):460-461.
7. Lee MJ, Lin EL. The use of the three-pronged Mayfield head clamp resulting in an intracranial epidural hematoma in an adult patient [published online ahead of print February 14, 2010]. *Eur Spine* J. 2010; 19(Suppl 2):S187-189.
8. Lee TH, Kim SJ, Cho do S. Broken mayfield head clamp [published online ahead of print May 31, 2009]. *J Korean Neurosurg Soc*. 2009; 45(5):306-308.
9. Moumoulidis I, Fernandes H. CSF rhinorrhea secondary to use of a Mayfield head clamp. *Ear Nose Throat J*. 2008; 87(7):E1-3.
10. Taira T, Tanikawa T. Breakage of Mayfield head rest. *J Neurosurg*. 1992; 77(1):160-161.
11. Yan HJ. Epidural hematoma following use of a three-point skull clamp [published online ahead of print April 25, 2007]. *J Clin Neurosci*. 2007; 14(7):691-693.
12. Chovanes GI. Breaks in Mayfield head holder. *J Neurosurg*. 1992; 77(6):977.